


**Manage TB**  
**National Institute for Research in Tuberculosis, Chennai**

**Lecture – 25**  
**Approach to diagnosis of Extra – Pulmonary Tuberculosis**  
**Case Discussion**

(Refer Slide Time: 00:12)



Manage TB

ICMR - National Institute for Research in Tuberculosis (NIRT)  
www.nirt.res.in

### Disclaimer

- This is a role play developed as part of the course curriculum for *Manage TB - An online course for Doctors*
- The participants have enacted the roles given to them
- The case discussed does not refer to any existing patient but has been developed as part of the course curriculum
- The investigations (x-rays/lab reports) used in this case scenario belong to patients treated in NIRT. Their identity have been anonymized.

Disclaimer this is a role play developed as part of the course curriculum for Managed TB An online course for Doctors. The participants have enacted the role given to them.

The case discussed does not refer to any existing patient, but has been developed as part of the course curriculum. The investigations x-rays and lab reports used in this case scenario, belongs to patients treated in NIRT. Their identity have been anonymized.

(Refer Slide Time: 00:35)



## Approach to diagnosis of Extra - Pulmonary Tuberculosis

### Case discussion

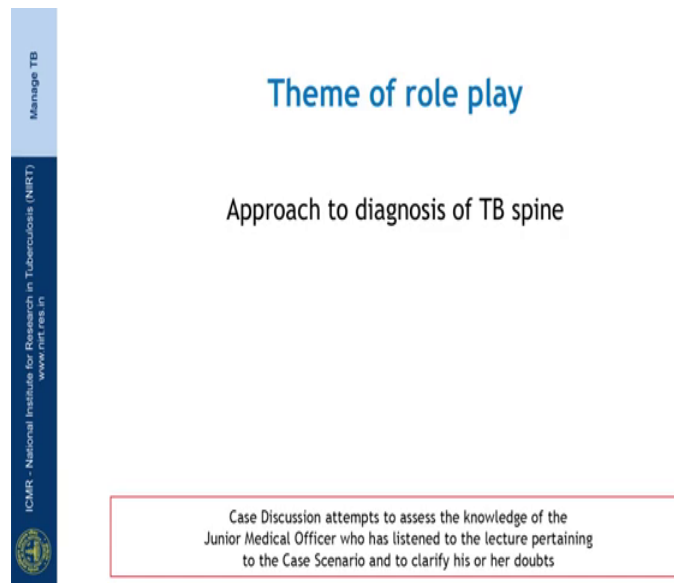
(Refer Slide Time: 00:40)



### Participants in the role play

- Chief Doctor
- Junior Medical Officer

(Refer Slide Time: 00:46)



Manage TB

## Theme of role play

Approach to diagnosis of TB spine

ICMR - National Institute for Research in Tuberculosis (NIRT)  
www.nirt.res.in

Case Discussion attempts to assess the knowledge of the Junior Medical Officer who has listened to the lecture pertaining to the Case Scenario and to clarify his or her doubts

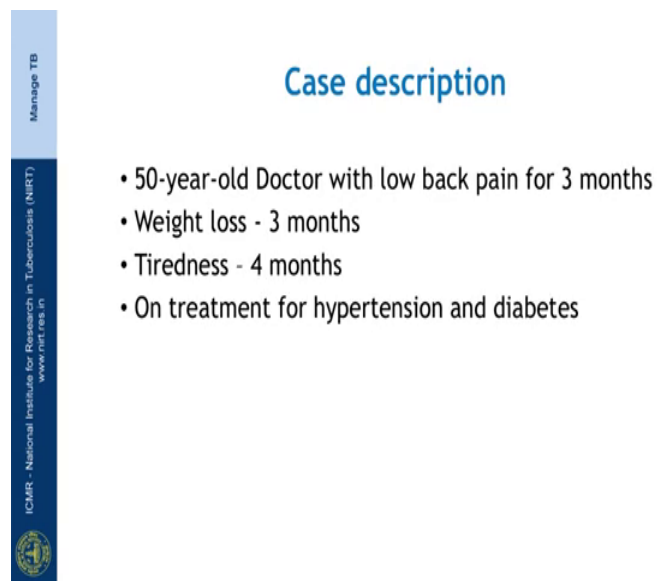
Good morning sir.

Good morning Dr. Uddesh.

Sir, I have a case to discuss with you. Is this an appropriate time sir?

Yeah, this is a right time we can discuss about the case too.

(Refer Slide Time: 00:57)



Manage TB

## Case description

- 50-year-old Doctor with low back pain for 3 months
- Weight loss - 3 months
- Tiredness - 4 months
- On treatment for hypertension and diabetes

ICMR - National Institute for Research in Tuberculosis (NIRT)  
www.nirt.res.in

Sir, we have a 50 year old man who is a Dr. with presenting complaints of low back pain for the past 3 months, loss of appetite and loss of weight for the past 3 months and generalized tiredness for the past 4 months sir. He is also known diabetic and then hypertensive on treatment.

Did you collect any additional details of history and do any clinical examination in this patient?

Yes sir, detailed history reveals that he has been having this back pain for the past 3 months which was incidence in onset and gradually progressive particularly, in the lumbar region. There is no pain in the cervical or the thoracic region sir, he also has low grade intermittent fever for the past 1 month.

His past history reveals that there was no treatment for tuberculosis previously and his nonreactive for HIV, since he is a known diabetic he has been on all hypoglycemic agents for the past 7 years with good glycemetic control. On clinical examination of his spine lower limbs reveals that there is mild tenderness in the lumbar region but with no deformity, his lower limbs shows no signs of wasting or any neurological deficit sir.

Based on the history and the clinical examination findings what do you think could be a presumptive diagnosis?

Sir, given his age I would like to first rule out the possibility for malignancy and also the possibility of a TB spine since he said non diabetic sir.

So good, we have to consider TB spine and malignancy in this patient. So, we have to order an MRI of the spine and you also have to order a chest radiograph to rule out any lung pathology.

Sir, what about an x-ray of that spine sir? Is it useful in diagnosing a TB case?

Certainly it would be useful, but the spinal lesions would take a 3 to 6 months to appear in the x-ray. So, a test of limited use in detecting the lesion earlier, so, it is where MRI is useful in detecting the lesions in the early stages of the disease and it will help us in understanding the extent of the lesion the magnitude of the bony destruction and the spinal cord involvement.

Ok sir, sir can I confirm and suggest treatment for TB just with the MRI findings?

Yeah, you can suggest treatment based on the MRI findings, but as I already mentioned they have to be careful and ruling out malignancy before we start him on TB treatment.

Sure sir.

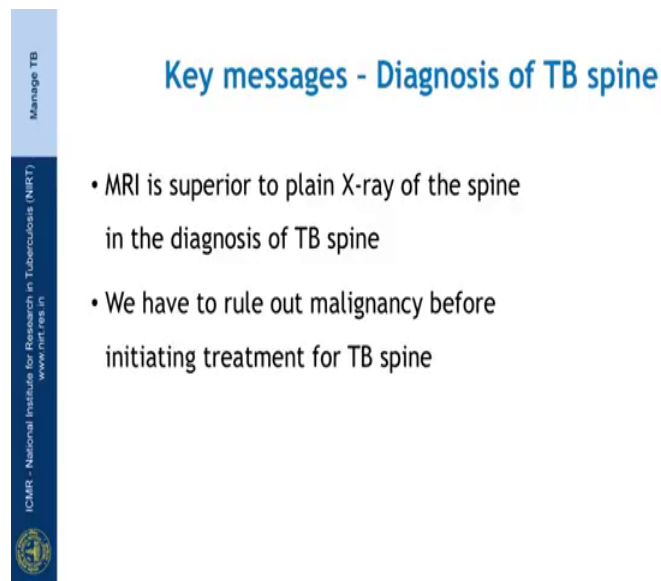
So you will start working on this patient?

Definitely, sir right away.

Can you summarize the discussions that we had now?

Definitely sir.

(Refer Slide Time: 03:19)



Manage TB

### Key messages - Diagnosis of TB spine

- MRI is superior to plain X-ray of the spine in the diagnosis of TB spine
- We have to rule out malignancy before initiating treatment for TB spine

ICMR - National Institute for Research in Tuberculosis (NIRT)  
www.nirt.ree.in

MRI is superior to plain X-ray of the spine in the diagnosis of TB spine. We have to rule out malignancy before initiating treatment for TB spine.